



PATIENT

Waffles Carter

PRESENTING CLINICAL SIGNS

History: Recheck echo. Doing well.
-Pertinent previous echo findings (1/2022 MD): Mild MR, no LA or LVE.

SPECIES

Canine

ECHOCARDIOGRAM FINDINGS

2D, m-mode, color flow and doppler imaging is available. Diffuse thickening of mitral valve leaflets (anterior>posterior) with mild prolapse into the left atrial lumen. Moderate eccentric mitral regurgitation with moderate left atrial dilation. Normal MR velocity. Mildly increased LV diameter with hyperdynamic myocardial function. The tricuspid valve appears subjectively normal, with trace tricuspid regurgitation. Normal right atrial and ventricular diameter. The pulmonic and aortic valves are normal in morphology and mobility. Normal pulmonic and aortic outflow velocities. No aortic or pulmonic insufficiency. No pericardial or pleural effusion noted. No cardiac tumors observed.

BREED

Miniature Schnauzer

SEX

Female Spayed

CARDIAC CHART

AGE

8.4 years

WEIGHT

16.8lbs

INTERPRETED BY

Maggie Machen Lamy,
DVM, DACVIM
(Cardiology)

CANINE CARDIAC PARAMETERS	MR VMAX (m/s)	TR VMAX (m/s)	LA/AO (Boon method)	LA/AO (Heart Base; Swe)	FS (%)	EF (%)	EPSS (cm)
NORMAL PARAMETER	4.5-5.5	<2.7	1.3	<1.6	28-40	40-100	<0.6
PATIENT	4.9		1.9	1.8	47	90	0.2
CANINE CARDIAC PARAMETERS	HR (BPM)	AV VMAX (m/s)	PV MAX (m/s)	BODY WEIGHT (kg)	LA 2D short axis Base view (cm)	LVIDd Avg; 2D and m-mode short axis (cm)	LVIDs Avg; 2D and m-mode short axis (cm)
NORMAL PARAMETER	50-100	0.7-1.7	0.7-1.6	BELOW	BELOW	BELOW	BELOW
PATIENT	NM	1.5	0.9	7.6	2.2	3.5	1.9
*Normal chamber parameters expressed as a mean value (SD)				3	1.27 (5.3)	2.46 (2.46)	1.36 (5.5)
BODY WEIGHT DEPENDENT PARAMETERS				5	1.40 (4.5)	2.74 (5.2)	1.60 (4.7)
*Note: All measurements based upon multi-modal images and methods. An average value is reported.				10	1.50 (3.8)	3.27 (3.5)	2.06 (3.1)
				15	1.83 (2.0)	3.71 (2.4)	2.43 (2.1)
				20	2.02 (1.9)	4.14 (2.2)	2.80 (2.0)
				25	2.18 (2.4)	4.48 (2.9)	3.10 (2.5)
				30	2.33 (3.3)	4.83 (3.9)	3.39 (3.4)
				35	2.48 (4.3)	5.17 (5.0)	3.69 (4.5)
				40	2.62 (5.2)	5.48 (6.1)	3.96 (5.4)
				50	2.88 (7.1)	6.07 (8.3)	4.46 (7.4)

Adapted from June Boon, Veterinary Echocardiography, 1998
Rishniw M and Hollis NE, J Vet Intern Med 2000; 14:429-435
Hansson et al, Vet Rad and Ultrasound 2002
Bonagura et al. Echocardiography: principles of interpretation, Vet Clin North Am 15:1177, 1995

IMAGING PERFORMED BY

Meredith Swart,
DVM

HOSPITAL NAME

Swart Veterinary
Imaging

REFERRING VET

Dr. Swart

INTERPRETATION OF THE FINDINGS & FURTHER RECOMMENDATIONS

Chronic degenerative valve disease persists with evidence of progression. Previously mild MR has advanced to moderate, with increasing left heart dimensions. Moderate left atrial enlargement indicates there is relatively low risk for imminent complication, however risk for progression to spontaneous congestive heart failure in the future is elevated. Additionally, a small tricuspid leak has developed; however, no obvious right heart enlargement is seen. No additional issues are identified.

INVOICE

32440

Based upon these findings, recommend institution of Pimobendan as below. Additionally, a baseline BP is recommended. Continued assessment of progression is recommended, with a

DATE

8/21/23



PATIENT

Waffles Carter

guarded prognosis going forward (stage B2). Patient may be at risk for development of CHF, arrhythmias, and/or sudden death going forward.

SPECIES

Canine

Omega fatty acid supplementation and mild salt restriction may also be of some long-term benefit. Monitor for development of a progressive cough, labored breathing, exercise intolerance or collapse episodes.

BREED

Miniature Schnauzer

Once on the medication for 3-5 days, anesthetic risk remains mildly elevated. Cardiac protective drug choices (opioid/benzodiazepine premedication, Propofol or alfaxalone induction, iso or sevo gas) are recommended. Monitor for arrhythmias, hypotension, and hypoxia both intra and post-operatively and intervene as necessary. Judicious IV fluid rates are recommended to avoid fluid overload. Avoid heart rate stimulating drugs such as atropine unless clinically indicated.

SEX

Female Spayed

PLAN

Baseline BP recommended every 6 months. Institute Pimobendan 0.25-0.3mg/kg PO q12h.

AGE

8.4 years

Recommend monitor for progression with a recheck echocardiogram in 6 months, sooner if any development of clinical signs.

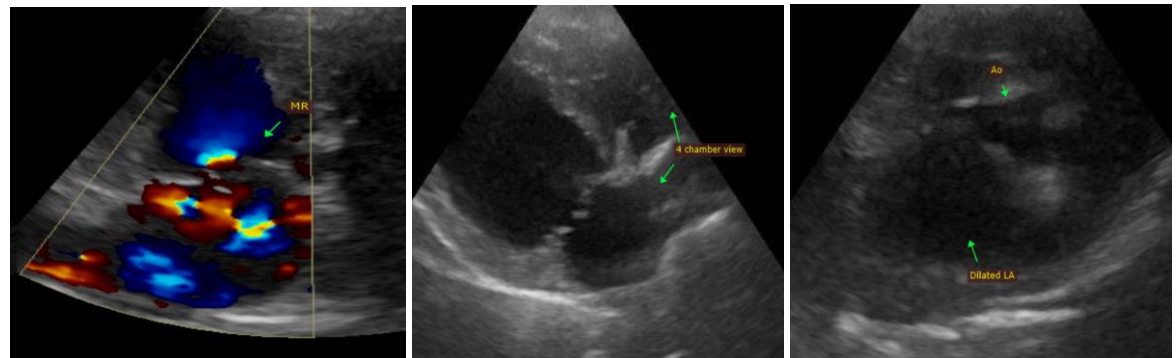
WEIGHT

16.8lbs

IMAGES

INTERPRETED BY

Maggie Machen Lamy,
DVM, DACVIM
(Cardiology)



IMAGING PERFORMED BY

Meredith Swart,
DVM

The information and recommendations provided are based on the images presented by the referring veterinarian. No evaluation can be communicated regarding pathology that was not visible in the image/video clips provided.

HOSPITAL NAME

Swart Veterinary
Imaging

Thank you for this referral. This report was generated using transcription software, and minor dictation errors may be present. If the clinical or image interpretation does not parallel your findings or if I can be of any further assistance, please contact me.

REFERRING VET

Dr. Swart

Maggie Machen Lamy, DVM
Diplomate of the American College of Veterinary Internal Medicine (Cardiology)
info@sonopath.com

INVOICE

32440

DATE

8/21/23